

A Simplified Marking for Vertical Breast Reduction and Mastopexy

TAMER ZAID, M.D.*; AHMED A.M. KHALIL, M.D.** and LOAI EL-BASSIONY, M.D.***

*Private Clinics in Kuwait**, *The Department of Plastic Surgery***, *Faculty of Medicine, Mansoura University and Private Clinics in Saudi Arabia****

ABSTRACT

This study was conducted on twenty three female patients. Their age ranged from 19 to 52 years. All were underwent vertical reduction mammoplasty in fifteen cases, mastopexy in three cases and auto-augmentation mastopexy in five cases.

The cases were collected from Plastic and Burn Surgery Department, Mansoura Faculty of Medicine, Egypt and private clinics in Kuwait and Saudi Arabia in the period between December 2012 and April 2015.

The aim of this study is to describe a simple way to mark the breast for vertical reduction mammoplasty and mastopexy to obtain a nice contour of the breast and to achieve the simplicity of these operations for young surgeons.

In Conclusion: We think that our surgical technique is one of the conservative surgical techniques that produce the least visible scars after excising excess folds of skin-envelop when either replacing, rearranging or augmenting the internal breast tissue.

Key Words: *Vertical reduction mammoplasty – Mastopexy.*

INTRODUCTION

Patients with macromastia and/or breast ptosis suffer from both physical and emotional problems, such as headache, neck, shoulder and back pain, shoulder strap grooving, shame and reduced self-esteem. Numerous studies have proven that breast reduction and breast ptotic surgery are safe and effective treatment for these symptoms. They restore normal function in daily activities, reduce pain, and improve quality of life and self-esteem within few months after surgery [1-3].

Psychologically, mastopexy and breast reduction procedures are not indicated by medical cause or physical reason; yet, by the self-image of the patient that is the combination of the physical, aesthetic and mental health requirement of the patient.

The evolution of mastopexy techniques has paralleled that of reduction techniques [4]. Four decades of reduction and mastopexy procedures followed and were aimed at transposing redundant tissue from the lower quadrants to fill the upper ones and retromammary area [5]. Many techniques were published in literature to correct breast reduction and mastopexy, each describing a way for marking and a way for glandular and/or skin resection. Descriptions of these techniques based on descriptions by Biesenberger, using a single medial pedicle [1928] and then that of Ragnell which employed two pedicles [6].

Vertical mammoplasty is one of these techniques which is firstly published by Lassus [7]. Although it is gained its popularity and acceptance because of its safety, long-lasting result and the good scar [8], most surgeons do not prefer to use considering it not suitable for large breasts and difficult for learning [9]. So, many authors are added their modifications to overcome these advantages [10-13].

Here, the authors applied a simple way to mark the breast for vertical reduction mammoplasty and mastopexy to obtain a nice contour of the breast and to achieve the simplicity of these operations for young surgeons.

PATIENTS AND METHODS

This study was applied on 23-female patients presented with huge breast and ptotic breast. Patient's age range from 19 to 52 years (mean 36.65 years). These patients seeking surgical interference for breast reduction (15 cases), mastopexy (3 cases) and auto-augmentation mastopexy (5 cases) were involved to our modification from

December 2012 to April 2015. This study was done in Plastic and Burn Surgery Department, Mansoura Faculty of Medicine, Egypt and private clinics in Kuwait and Saudi Arabia.

Preoperative evaluation:

Preoperative assessment includes history taking, general and breast examination to evaluate medical fitness of patients for surgery and to evaluate location of NAC, degree of breast ptosis, breast volume and its contour and skin elasticity. We were making sure that our patients are non-smokers and off medications that may make bleeding more likely. To all our patients, we explained the procedure in detail and go over the risks and what the recovery will be like. Mammogram was done for all patients as a baseline for comparison which is important for the patient who complains firmness after surgery. Photography was taken for all patients as apart of preoperative and postoperative clinical assessment for an exact evaluation of our results.

Preoperative marking:

The marking were drawn while the patient was upright. The breast meridian and the inframammary (IMF) were marked. The proposed nipple location was marked over the breast meridian, opposite or just below IMF. This would put the nipple about 22-26cm from the suprasternal notch, depending on patient height and desired breast size (the smaller the size, the higher the nipple). The areola diameter was set between 4 and 5cm. Mark the upper margin of the new NAC 2 – 2.5cm above the newly located nipple (according to areola size). Then draw a circle from the location point of the new NAC around the original areola. From the lower arc of that circle, two vertical lines, medial and lateral, were drawn down to a level 4cm above IMF. The medial line was drawn by lateralizing the breast then draws it from the nipple downwards perpendicularly. While the lateral one was drawn by pushing the breast medially, then drop it from the nipple. Safe closure was checked by pinching these two lines together.

Procedure:

The areola, the circle, two vertical lines down to the horizontal line and the horizontal line between 2 vertical lines were incised. The overlying skin of the marked part between the incised lines was de-epithelialized. The pedicle was designed superiorly in all cases of mastopexy and nine cases of reduction mammoplasty. In the remaining reduc-

tion cases, the pedicle was designed medially. The pedicle base was at least 7cm and more for longer pedicles. The lower de-epithelialized inferior dermoglandular part 2cm at least below the inferior areola border was excised down to the pectoral fascia in reduction cases. While in auto-augmentation mastopexy, it was dissected from the pectoral fascia and extends the dissection deep to the superior pedicle to create a pocket. No tissue was excised in mastopexy but only cut and released from both medial and lateral flaps. NAC was transposed to the new position. In auto-augmentation mastopexy cases, the lower de-epithelialized inferior dermoglandular flap was turned over and fixed with 2/0 non-absorbable sutures to the pectoral fascia underneath the superior pedicle opposite the 2nd or 3rd rib. The two vertical lines extend to meet below the horizontal line about 2cm above the IMF. Temporary closure skin edges of both medial and lateral flaps were done. Patient was brought in sitting position and adjusted the projection, asymmetry and shape on both sides. Then, the areas of excess were excised with the excision of the dog-ear if needed. The drains were inserted, the medial and lateral pillars were approximated with absorbable sutures and the incision lines were sutured in 2 layers; deep dermal and subcuticular. Areola was closed in a circular manner.

Post-operative care:

We checked the nipple color and its vascularity after 24 hours. The drains were removed after 24-48 hours in all patients. The size and shape of the breast usually improve as time passes after surgery. So, we recommended our patients to wear special bra to provide support of the breast during recovery time.

RESULTS

Twenty three female patients were included in this study. The average follow-up period was 4 months. An evaluation of our results was based on preoperative and postoperative photos and patient satisfaction. All patients tolerated the procedure and recovered well with no major deformity, specific complications or asymmetry. In this study, the maximum tried NAC transposition was 10cm (ranged from 6-10cm) and the maximum resected breast tissue was 1150 gram on each side (ranged from 500-1150 grams). All patients achieved a good aesthetic contour of the breast with minimal scar and an excellent patient satisfaction.

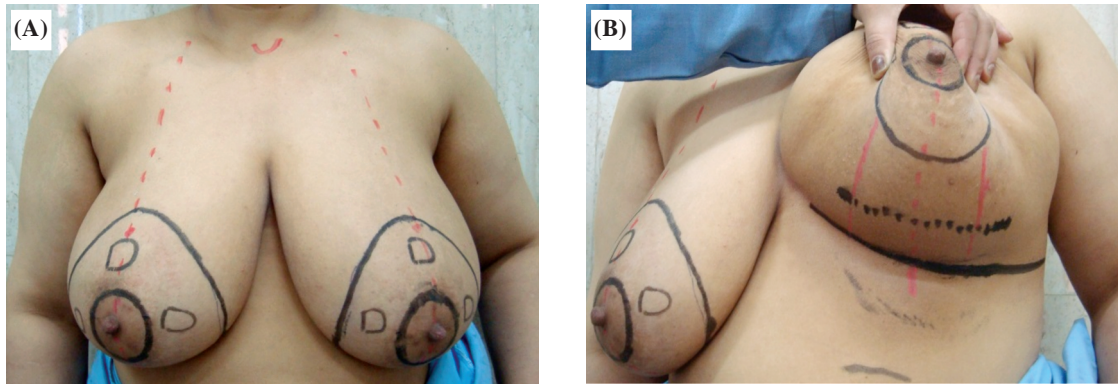


Fig. (1): Marking of the breast (A and B).

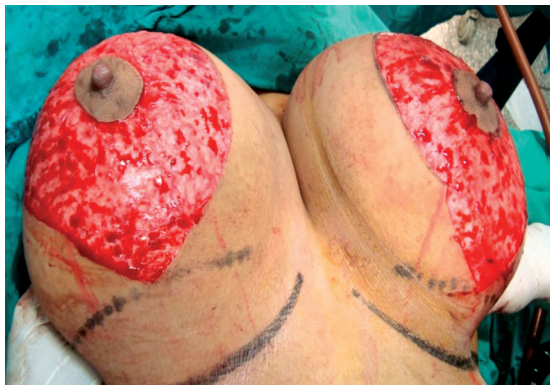

Fig. (2): De-epithelialization.

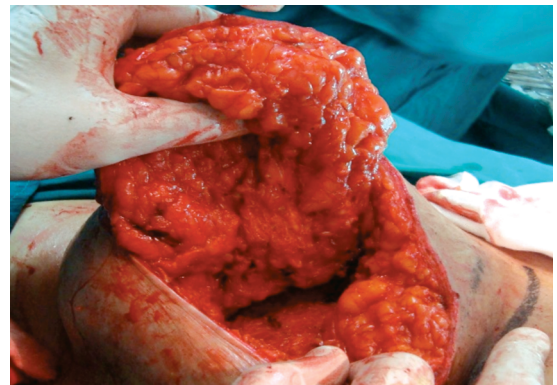


Fig. (3): Elevation and dissection of lower flap.

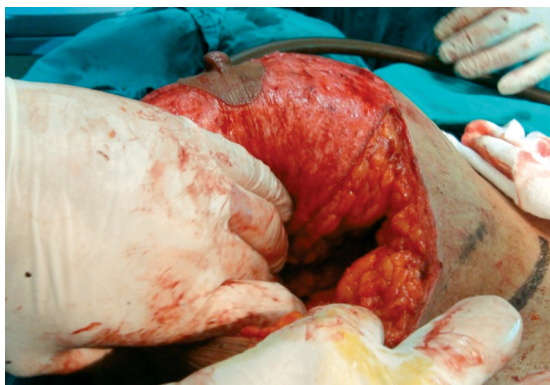

Fig. (4): Turnover the flap.

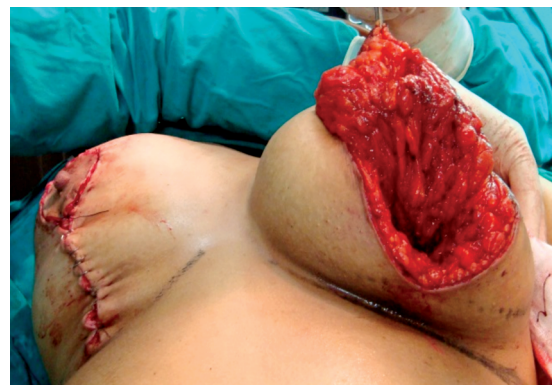

Fig. (5): Temporary closure.

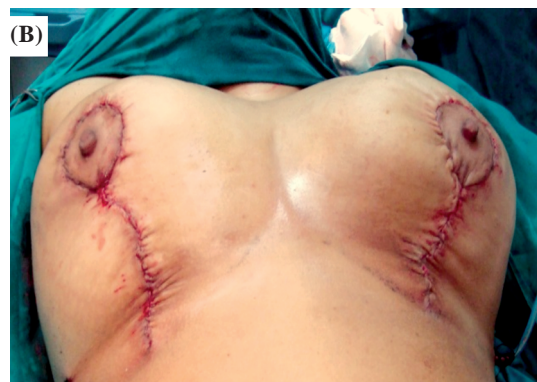
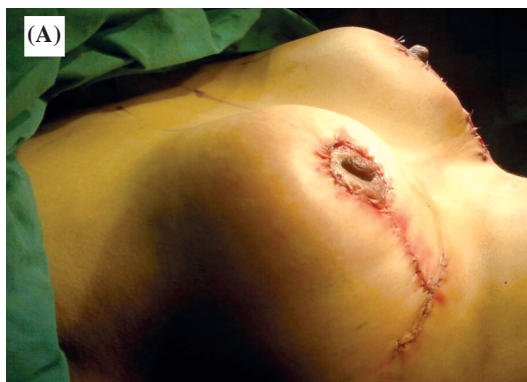
Fig. (6): Closure of the skin and areola (A: Small inverted T closure, B: Vertical limb closure).

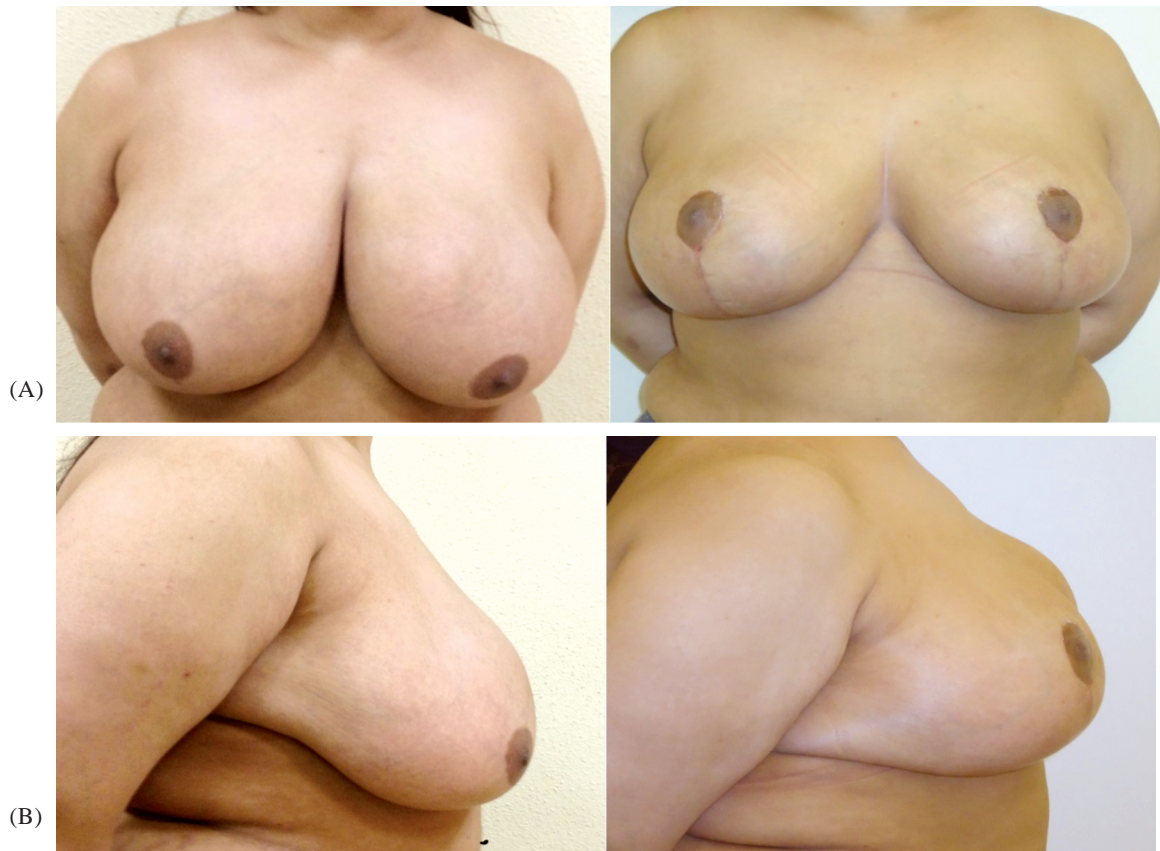

Fig. (7): Pre- and postoperative views (A: Anterior view, B: Lateral view).

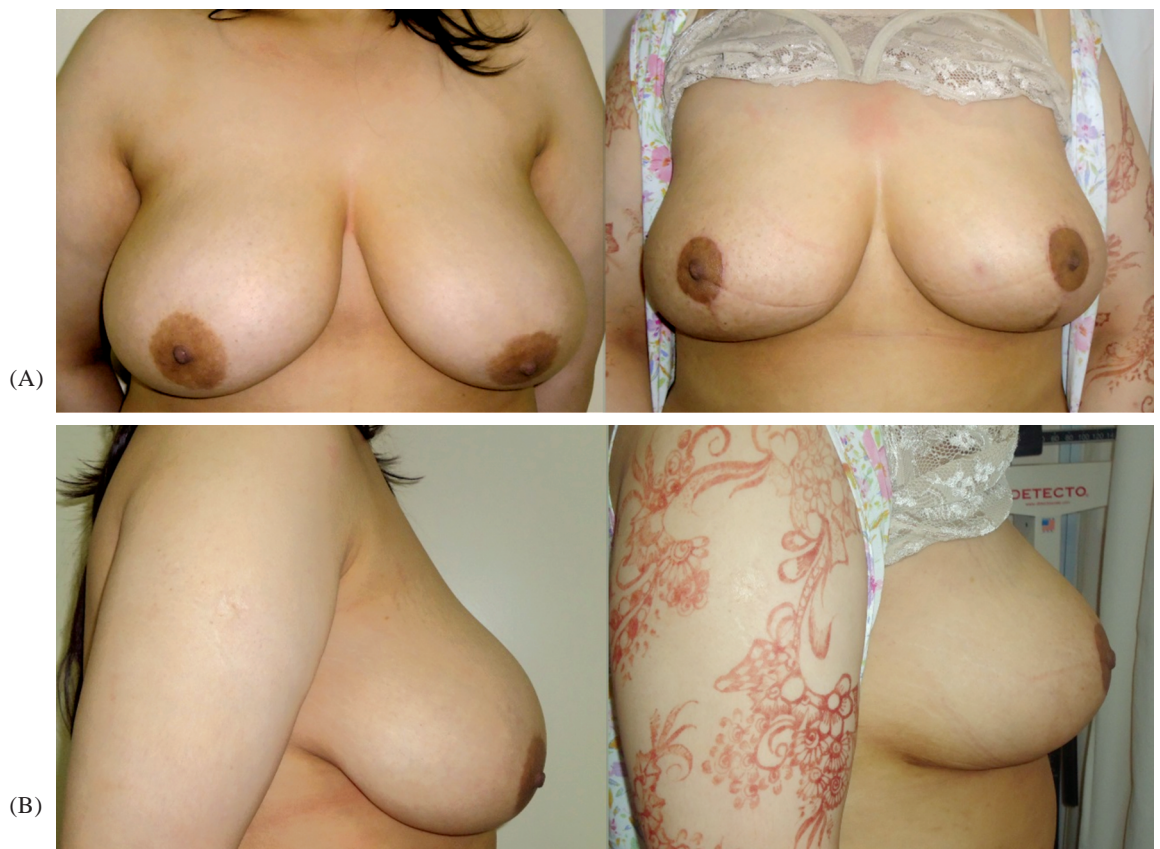

Fig. (8): Pre- and postoperative views (A: Anterior view, B: Lateral view).

DISCUSSION

Reduction mammoplasty and mastopexy still arguing topics due to each procedure has different parameters. Moreover, the young plastic and reconstructive surgeon are often challenged these operations because they require proper marking and suitable operative time.

Improper marking of the breast leads to faulty correction, asymmetry, abnormal NAC positioning. So, this study aimed to describe a simple marking plan successfully treats the hypertrophied breast tissue, skin redundancy associated with safe transposition of NAC.

In reduction mammoplasty and breast-lift surgery to re-establish an aesthetically proportionate bust for women, the critical corrective consideration is the tissue viability of the nipple areola complex, so that the outcome is a functionally sensate breast of natural size, contour and feel.

Mastopexy-augmentation procedure features increased surgical complication rates when compared to the lesser complication rates of breast augmentation and mastopexy as discrete surgical operations [14]. Recent studies of a newer technique for simultaneous augmentation mastopexy (SAM) indicate that it is a safe surgical procedure with minimal medical complications [15]. The SAM technique involves invaginating and tacking the tissue first, in order to previsualize the final result, before making any surgical incisions to the breast [16].

This approach has the standard advantages of the vertical mammoplasty. These advantages includes; tolerated marking for all patients, safe for all sizes of breasts as the pedicle become large in large breast to maintain the vascularity of the nipple-areola complex, good projection of the breast, shorter operative times, long-lasting results, limited scars and minimal postoperative complications [17].

In addition, this approach is easy to teach and learn and malleable to change the pedicle design (superior, medial or lateral) in reduction mammoplasty after de-epithelialization and resection of the inferior dermoglandular flap to allow more excision of breast tissues.

Conclusion:

Breast reduction and breast-lift techniques are known according to the number of scars produced, which is related to the achievable degree of elevation of the nipple areola complex. In realizing this issue, we think that our surgical technique is one

of the conservative surgical techniques that produce the least visible scars after excising excess folds of skin-envelop when either replacing, rearranging or augmenting the internal breast tissue.

REFERENCES

- 1- Behmand R.A., Tang D.H. and Smith D.J.: Outcomes in breast reduction surgery. *Ann. Plast. Surg.*, 45 (6): 575-580, 2000.
- 2- O'Blenes C.A.E., Delbridge C., Miller B., Pantelis A. and Morris S.: Prospective study of outcomes after reduction mammoplasty: Long-term follow-up. *Plast. Reconstr. Surg.*, 117 (2): 351-358, 2006.
- 3- Mello A., Domingos N.A.M. and Miyazaki M.C.: Improvement in quality of life and self-esteem after breast reduction surgery. *Aesthetic Plast. Surg.*, 34 (1): 59-64, 2010.
- 4- Aston S.J. and Rees T.: Breast reduction and mastopexy. In Rees T., editor: *Aesthetic Plastic Surgery*, Philadelphia, WB Saunders, 1980.
- 5- Felicio Y.: Peri-areolar reduction mastopexy. *Plast. Reconstr. Surg.*, 88 (5): 789-798, 1991.
- 6- Tessier P. and Wolfe S.: Breast reduction with dermoglandular flaps. *Ann. Plast. Surg.*, 67 (6): S42-S54, 2011.
- 7- Lassus C.: Possibilities et limites de la chirurgie plastique de la silhouette feminine. *L'Hospital*, 801: 575, 1969.
- 8- Nahai F.: Vertical reduction. *Operative Techniques in Plastic and Reconstructive Surgery*, 6 (2): 97-105, 1999.
- 9- Hall Findlay: A simplified vertical reduction mammoplasty: Shortening the learning curve. *Plast. Reconstr. Surg.*, 104 (3): 748-759, 1999.
- 10- LeJour M.: Vertical mammoplasty and liposuction of the breast. *Plast. Reconstr. Surg.*, 94: 100-114, 1994.
- 11- Marchac D. and De Olarte G.: Reduction mammoplasty and correction of ptosis with a short inframammary scar. *Plast. Reconstr. Surg.*, 69: 45-55, 1982.
- 12- Marchac D. and Sagher U.: Mammoplasty with a short horizontal scar. Evaluation and results after 9 years. *Clin. Plast. Surg.*, 15: 627-639, 1988.
- 13- Marconi F. and Cavina C.: Reduction mammoplasty and correction of ptosis: A personal technique. *Plast. Reconstr. Surg.*, 9: 1046-1056, 1993.
- 14- Spear S.L., Boehmler J.H. I.V. and Clemens M.W.: Augmentation-mastopexy: A 3-year Review of a Single Surgeon's Practice. *Plast. Reconstr. Surg.*, 118 (7 Supplement): 136-151, 2006.
- 15- Eisenberg T.S.: Simultaneous Augmentation Mastopexy: A technique for Maximum En Bloc Skin Resection Using the Inverted-T Pattern Regardless of Implant Size, Asymmetry, or Ptosis. *Aesthetic Plastic Surgery*, 36 (2): 349-354, 2011.
- 16- Eisenberg T.S.: Augmentation Mastopexy for Moderately to Severely Ptotic Breasts: Previsualizing Breast Shape and Symmetry with the Innovative and Versatile Staple-First Technique. *American Journal of Cosmetic Surgery*, 26 (3): 168-176, 2009.
- 17- LeJour M.: Vertical mammoplasty for breast hypertrophy and ptosis. *Operative Techniques in Plastic and Reconstructive Surgery*, 3 (3): 189-198, 1996.